

An outbreak of kerato-conjunctivitis among corralled, supplementary fed, semi-domestic reindeer calves.

Claes Rehbinder¹ & Anna Nilsson²

¹ National Veterinary Institute, P.O. Box 7073, S-750 07 Uppsala, Sweden.

² Department of Animal Nutrition and Management, Swedish University of Agricultural Sciences, P.O. Box 7023, S-750 07 Uppsala, Sweden.

Abstract: The winter 1993–94 was hard with periods of severe cold and a thick snow layer. In the beginning of January 1994, approximately 500 reindeer calves were separated from the main herd and corralled for supplementary feeding. During this period around 30 calves died by emaciation and other circumstances related to the change in feeding regimes. Fourteen days later, the calves were rounded up, lassoed and transported around 50 km to another corral. The animals, under severe stress and underfed were offered an insufficiently pelleted feed. After two days, some animals showed signs of eye irritation and on the third and fourth days, several calves had developed unilateral or bilateral kerato-conjunctivitis and blindness. The remaining 390 calves, were slaughtered at the end of January. During the time spent in the second corral, around 80 calves died by emaciation, some of them were blind. Around 300 calves were then, or had been, affected. Of these about 240 were unilaterally blind and 60 bilaterally blind. Bacteriological, virological, electron-microscopical and histopathological investigations showed that fodder particles in the conjunctival sac caused the primary lesions which were secondarily invaded by opportunistic bacteria. The stressful situation of the calves may have contributed to the severity and the rapid development of the lesions.

Key words: Kerato-conjunctivitis, *Rangifer tarandus*, supplementary feed

Rangifer, 15 (1): 9–14

Background

The winter 1993–94 was hard with long periods of severe cold and a thick snow layer. At the end of the year 1993, the herdsmen of Luoktamavas Saami group spent one week gathering their whole herd (several thousand animals) for rounding up and sorting out. On January 4th, 500 calves were separated from the rest of the herd. Thereafter the calves were supplementary fed in a corral (Stenudden) for two weeks. Fourteen days later they were transported about 50 km by lorry, to Vuolda, a large establish-

ment with several corrals and a reindeer research station. During the night between the 18th and 19th January the calves were kept together in one corral but on the 20th they were divided into two groups. All the calves were lassoed. On the 20th January a few animals showed signs of eye irritation. By the 24th of January about 50 % of the calves showed different stages of kerato-conjunctivitis. From the 26th of January till the 2nd of February some of the calves received a single daily treatment of eye ointment (Aureomycin 1 % Lederle). As no

veterinary surgeon was available to give subconjunctival injections of antibiotics, the reindeer owners had to treat the animals themselves. On the 27th, blood samples, bacteriological samples and virological samples were collected and transported to Uppsala. On the 2nd February, all remaining calves were slaughtered after having been fed supplementary food for 30 days. Material for pathological examination was sent to the National Veterinary Institute, Uppsala.

During the two weeks at Stenudden some 30 animals died by emaciation and because of other circumstances related to change in feeding regimes. The pelleted feed used was *Renfor bas (Fori)*. It arrived in several consignments, the second of which had not been sufficiently pelleted and contained large quantities of a coarse, meal-like content, and was the one used during the first week in Vuolda. Two kinds of cribs were used, one kind being troughs, 2 meters in length, and the other type being home made automatic feeders. In Stenudden ten cribs were used for all the 500 animals. In Vuolda eight cribs and twelve automatic feeders were used for about 470 calves. The calves always rapidly consumed all the fodder given. In Vuolda intense crowding around the cribs was seen and the calves were vigorously fighting and treading on each other in order to reach the food in the cribs. When food was within reach they often pushed their nose deep into it, eagerly trying to consume as much as possible, while at the same time fighting to remain in position. When snorting, panting, and dipping their heads deep down into the fodder a lot of dust was produced. Problems related to the supplementary feeding continued during this period and approximately 80 of the about 470 animals at Vuolda died from diarrhoea and emaciation. A number of these calves were also uni- or bilaterally blind.

Eye lesions

Eye lesions characterized by conjunctivitis appeared two days after the animals had reached Vuolda. The primary lesion was a mucopurulent conjunctivitis showing hyperemia also of the sclera and markedly swollen eye lids. Out of the conjunctival sacs poured thick, yellow pus, which froze to lumps under the eye (Fig 1). Blood stained snow was seen where the calves had been resting. After the eyelids had been swollen for 2-4 days the cornea became grey, starting at the limbus (Fig 2). The calves appeared blind in the affected eyes. According to the herders, approximately 300 calves (65 %) became blind. Out

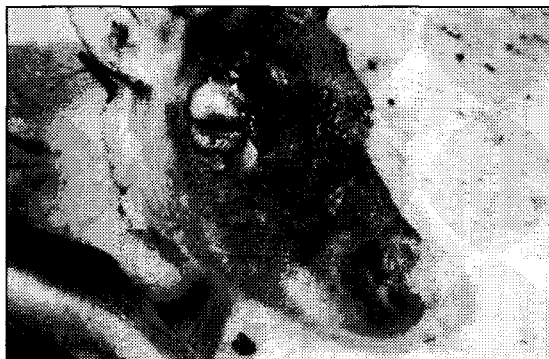

Fig. 1. Reindeer calf suffering from kerato-conjunctivitis. Note the photophobia, swollen eyelids and the frozen pus on the lower eyelid. Photo: A. Nilsson.

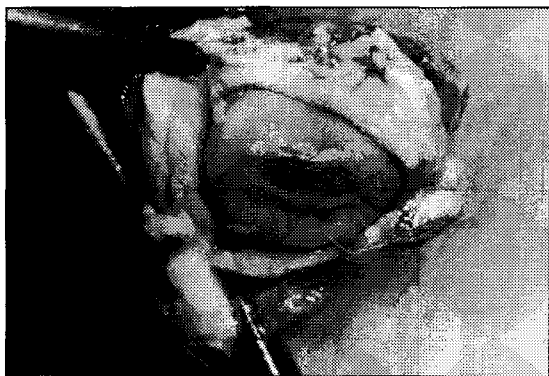


Fig. 2. Eye of reindeer calf. Note the very marked peripheral swelling of the cornea. Photo: B. Ekberg.

of these about 20 % or around 60 animals were bilaterally blind, often in different stages of disease, while the remaining were unilaterally blind. When feed was presented to the animals, the sick calves had problems competing at the cribs. In addition they did not run away from people and the reindeer owners sometimes called them «tame calves». On the 26th January most of the calves were treated with Aureomycin 1 % eye ointment. After two days of single dose daily treatment these animals seemed to improve. The effect was temporary and there was no significant improvement after five days' treatment. The 119 reindeer calves kept at Vuolda for research purposes, at the same place but fed silage, all remained healthy.

Material and methods

Sampling

On the 27th January samples were taken from the

Table 1. Bacterial growth in investigated eyes from blind reindeer calves.

Eye no.	Bacterial growth	Remarks
1.	Moderate growth of <i>Pasteurella multocida</i> in mixed culture.	Initial sample, keratoconjunctivitis.
2.	Moderate growth of <i>Pasteurella multocida</i> . Moderate growth of <i>Actinomyces pyogenes</i> .	Initial sample, keratoconjunctivitis.
3.	Sparse growth of <i>Pasteurella multocida</i> in mixed culture.	Initial sample, keratoconjunctivitis.
4.	Sparse growth of <i>Pasteurella multocida</i> in mixed culture.	Keratoconjunctivitis.
5.	Moderate growth of haemolysing <i>Moraxella sp.</i>	Keratoconjunctivitis.
6.	Moderate growth of <i>Pasteurella multocida</i> in mixed culture.	Keratoconjunctivitis.
7.	Moderate growth of <i>Pasteurella multocida</i> . Sparse growth of haemolysing <i>Moraxella sp.</i>	Keratoconjunctivitis.
8.	Sparse growth of haemolysing <i>Moraxella sp.</i>	Keratoconjunctivitis.
9.	Moderate growth of <i>Pasteurella multocida</i> . Moderate growth of <i>Klebsiella sp.</i>	Normal eye. Anterior chamber no growth
10.	Moderate growth of <i>Pasteurella multocida</i> . Moderate growth of <i>Actinomyces pyogenes</i> .	Keratoconjunctivitis. Necropsied calf.
11.	Moderate growth of <i>Pasteurella multocida</i> . Moderate growth of <i>Actinomyces pyogenes</i> .	Keratoconjunctivitis. Necropsied calf.

eyes of infected but untreated calves. Bacteriological samples were taken from three animals and samples for virology from three other calves. In addition, at slaughter, the eyes from ten reindeer calves were submitted for investigation. Nine of these calves were bilaterally blind. From the remaining unilaterally blind calf the normal eye was removed. A bilaterally blind slaughtered reindeer calf was also sent for necropsy to the National Veterinary Institute, Uppsala.

Bacteriology

Swab samples in transport media (Stuart medium (Copan, Italy)) from the conjunctival sac of one eye from each of three untreated, bilaterally affected animals, were collected. One eye from each of ten other animals was removed after slaughter. The eyes were sent chilled, to The National Veterinary Institute. Bacteriological samples were obtained from the conjunctival sacs and from the anterior chambers of six of these eyes and from the eyes of the necropsied calf. The samples were cultured on blood agar base n:2 (Lab. M.) with 5 % horse blood, and on lactose-bromocresol purpur agar (SVA) incubated in 37°C and observed after 48 hours.

Virology

From three animals, other than those sampled for bacteriology, swab samples kept in transport medium (buffered tryptose-phosphate broth, gelatin, chloramphenicol, cyclohexamid (Copan, Italy)) and blood were collected. The blood was submitted to the laboratory with EDTA as anticoagulant, and as serum.

Histology

The ten eyes obtained as unfixed material, and the eyes from the necropsied calf, were carefully inspected. They were then cut open, inspected, fixed in 10 % formalin, embedded in paraffin, cut 5 µ and stained with haematoxylin-eosin, toluidin blue, and according to van Gieson, Giemsa, and Grocotte.

Electron microscopy

Small pieces from different parts of the cornea and conjunctiva (2 x 3 mm), from six of the eyes sampled and the eyes of the necropsied calf, were fixed in Karnovsky, postfixed for 4 h in 1 % OsO₄ with 0,1 mol/l phosphate buffer before embedding in TAAB 812. Sections were stained with uranyl acetate and lead citrate and examined in an electron

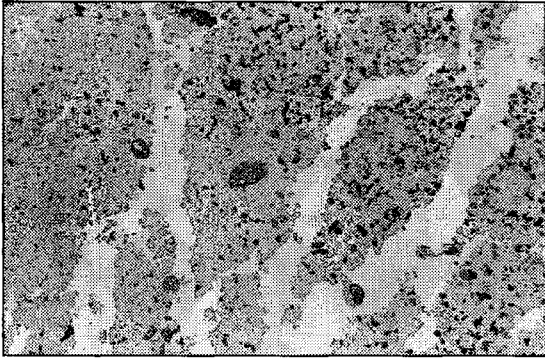


Fig. 3. Plant particles on the conjunctiva. Note the necrotic mucosa and the strong inflammatory reaction. HE 180x. Photo: C. Rehbinder.

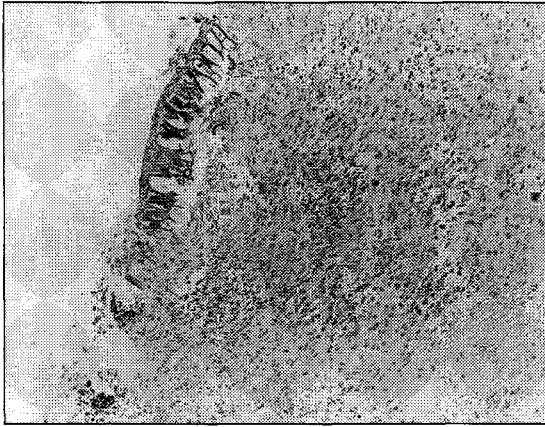


Fig. 4. Plant particles in the necrotic conjunctival submucosa. HE 180x. Photo: C. Rehbinder.

microscope, at 60 kw and magnifications varying between 500 and 40,000 times.

Results

Necropsy

The necropsied animal died from emaciation. In the final stage a general infection with *P. multocida* may have contributed to the death. The animal was bilaterally blind. The gross and histological findings in its eyes were similar to those seen in the other eyes sampled. In addition a marked rhinitis and minor lesions in the oral mucosa indicative of a herpes virus infection were present.

Bacteriology

The results of the bacteriological investigation are shown in Table 1. Conjunctiva and anterior chamber yielded the same growth for all eyes, except for

the normal eye from which no growth of bacteria was recorded from the anterior chamber.

The necropsied calf revealed a moderate growth of *P. multocida* in mixed culture in the nasal cavities and a moderate growth of *P. multocida* in pure culture in the body lymph nodes.

Virology

Virological investigations, including serology and culture, yielded negative result for bovine virus, diarrhoea virus and IBR/IPV virus, (herpes virus) (Rockborn *et al.*, 1990).

Histology

The conjunctiva of all eyes, except for the normal eye, showed an intense purulent, partly necrotising inflammation. Plant material was found on the surface and deep in the necrotic masses (Figs 3–4). The cornea was 5–6 times thicker than normal. Its thickness was especially pronounced in the periphery due to a severe oedema. There was a marked penetration of capillaries and a severe infiltration of neutrophils. In three out of ten cases small foci of eosinophils were present. In three cases necrotic foci and a total loss of normal epithelium were seen. In eight out of ten eyes, a purulent iridocyclitis and hypopyon were found. There were no indications of necrobacillosis or fungal infection. The normal eye showed a normal thickness of the cornea (Winqvist & Rehbinder, 1973; Rehbinder *et al.*, 1977) and no pathological lesions.

Electron microscopy

The ultrastructural investigation confirmed the histological investigation. No virus particles were observed.

Discussion

Kerato-conjunctivitis is not uncommon in reindeer (Bergman, 1912; Hadwen & Palmer, 1922; Nordqvist, 1966; Skjenneberg & Slagsvold, 1968; Kummeneje, 1976; Rehbinder, 1978; Barker, 1980). Rehbinder (1978) proved the regularly appearing summer outbreaks of keratitis in forest reindeer to be a result of the herding conditions causing numerous conjunctival and corneal lesions as well as bacterial infection.

It seems obvious that also the present outbreak is caused by management factors. The anamnesis and the morphological and microbiological investigations strongly indicate that the disease was mainly caused by plant particles, from insufficiently pel-

leted feed, primarily causing conjunctivitis which became secondarily infected by bacteria which are normally found on the oral and nasal mucosa (Rehbinder & Glatthard, 1977; Rehbinder, unpublished). These bacteria may also be subclinically carried in the conjunctiva (Rehbinder, 1977) as exemplified in this case by the normal eye (no 6, Table 1). The investigations performed revealed no indications of mycoplasma, rickettsia, or virus (Rehbinder, 1977). The clinical and pathological picture carried no similarities to the pox virus induced kerato-conjunctivitis in reindeer, as reported by Barker *et al.* (1980).

The clinical and pathological picture of the kerato-conjunctivitis seen during wintertime, in connection with supplementary feeding, differs from that of the regularly appearing summer outbreaks of the disease (Rehbinder, 1978). The primary lesion during summer outbreaks is mainly affecting the centre of the cornea (Rehbinder, 1978) while in the winter outbreak described the primary lesion was that of a severe conjunctivitis.

It is evident from the fighting seen among the calves that too few cribs were used and the anamnesis indicates that the calves were underfed, leaving some of them to die from emaciation. In addition, the severe cold during the period the calves were kept in the corrals presumably increased their energy demand, as seen from feeding experiments in progress at the research station (Nilsson, 1994 unpublished observations).

Hence, stress may have played an important role. In addition, the calves were lassoed several times before, during and after the transport to Vuolda and were also exposed to various other management measures such as sorting, change of corral etc., which are known to be stressful to the animals (Rehbinder, 1990). Fighting for food most certainly also increased the stress. The reindeer calf obtained for necropsy revealed lesions indicative of a herpes virus infection (Rockborn *et al.*, 1990). This virus is known to be present, with varying prevalence, in reindeer populations (Rehbinder *et al.*, 1986; Rehbinder *et al.*, 1991) and to cause manifest disease under stressful conditions (Rockborn *et al.*, 1990). One of the mucosal lesions produced by the virus is a conjunctivitis which, in circumstances like the ones at Vuolda, may act as a predisposing factor for further eye involvement. The stressful situation of the calves may have contributed to the severity and the rapid development of the lesions. To avoid outbreaks of kerato-conjunctivitis among reindeer,

fed supplementary pelleted fodder, it is therefore important to prevent stressful conditions and to reduce stress by providing ample space and enough fodder to allow all the animals to feed undisturbed. The feed must also be checked for satisfactory pellet quality. Since the outbreak in Vuolda became known, several similar outbreaks have been reported. Measures, such as those described above have successfully limited further spread of the disease.

References

- Barker, I. K., Mehren, K. G., Rapley, W. A. & Gagnon, A. N. 1980. Keratoconjunctivitis and oral/cutaneous lesions associated with pox virus infection in reindeer. – In: R. J. Montar & G. Migaki (eds.). *The comparative pathology of zooanimals*. Smithsonian Institution Press. Washington D. C. USA, pp 171–177.
- Bergman, A. 1912. Contagious keratitis in reindeer. – *Scand. Vet. -T.*, 2: 145–177.
- Hadwen, S. & Palmer, L. J. 1922. *Reindeer in Alaska*. U.S. Department of Agriculture. Bulletin no. 1089, Washington.
- Kummeneje, K. 1976. Isolation of *Neisseria ovis* and a colesiota conjunctivae-like micro-organism from cases of keratoconjunctivitis in reindeer in northern Norway. – *Acta vet. scand.* 17: 107–108.
- Nikolawskii, L. D. 1968. Disease of reindeer. – In: P. S. Zhigunov (ed.). *Reindeer Husbandry*. Moscow. Israel program for scientific translations, Jerusalem. 348 pp. (First publ. in Russian in 1961).
- Nordqvist, M. 1966. Diseases of Reindeer. – In: *Ekonomisk Renskötsel*. Borås, pp 106–141.
- Rehbinder, C. & Glatthard, V. 1977. Keratitis in reindeer. Relation to bacterial infections. – *Acta vet. scand.* 18: 54–64.
- Rehbinder, C. 1977. Keratitis in reindeer. Investigations of mycoplasma, rickettsia, rickettsia-like organisms and virus. – *Acta vet. scand.* 18: 65–74.
- Rehbinder, C., Winqvist, G. & Roos, C. 1977. Structure of the cornea of some cervidae. – *Acta vet. scand.* 18: 152–158.
- Rehbinder, C. 1978. *Keratitis in reindeer. A study of ethiological factors*. – Ph. D. Thesis. Uppsala. University of Agricultural Sciences.
- Rehbinder, C., Nordkvist, M., Moreno, J. W. & Islam-Ud-din Siddiqui. 1986. A suspected virus infection of the oral mucosa in Swedish reindeer (*Rangifer tarandus* L.). – *Rangifer*, Special Issue No. 1: 369–373.
- Rehbinder, C., Belak, S. & Nordkvist, M. 1992. A serological retrospective study in reindeer on five different viruses. – *Rangifer* 12 (3): 191–195.
- Rehbinder, C. 1990. Management stress in reindeer. – *Rangifer*, Special Issue No. 3: 267–288.
- Rockborn, G., Rehbinder, C., Klingenborn, B., Leffler, M., Klintevall, K., Nikkilä, T., Landen, A. & Nordkvist, M. 1990. The demonstration of a herpes

virus, related to bovine herpesvirus 1 in reindeer with ulcerative and necrotizing lesions of the upper alimentary tract and nose. – *Rangifer*, Special Issue No. 3: 373–384.

Skjenneberg, S. & Slagsvold, L. 1968. *Reindriften og dens naturgrunnlag. (Reindeer Husbandry and Its Ecological Principles.)*. Universitetsforlaget, Oslo/Bergen/Tromsø. 332 pp.

Williams, E. S., Becerra, V. M., Thorne, E. T., Graham, T. J., Owens, M. J. & Nunamaker, C. E. 1985. Spontaneous pox viral dermatitis and keratoconjuncti-

vitis in free-ranging mule deer (*Odocoileus hemionus*) in Wyoming. – *J. Wildl. Dis.* 21 (4): 430–433.

Winqvist, G. & Rehbinder, C. 1973. Fine structure of the reindeer cornea in normal conditions and in keratitis. – *Acta vet. scand.* 14: 292–300.

Manuscript accepted 2 February, 1995