

A suspected virus infection of the oral mucosa in Swedish reindeer (*Rangifer tarandus* L)

C. Reh binder¹, M. Nordkvist¹, J. W. Moreno² and Islam-Ud-Din Siddiqui³.

Abstract: In 1980 a rather high frequency of reindeer, supplementarily fed in pens, were taken ill and deaths occurred as well. In five out of eight carcasses necropsied oral lesions were observed. Histologically the mucosa, surrounding these lesions, was characterized by the presence of intracytoplasmic inclusion bodies, inter- and intracellular oedema and vesicle formation. *Fusobacterium necrophorum*, *Coli*, beta haemolyzing streptococci, and *Corynebacterium pyogenes* found in the lesions were all considered secondary invaders. Serological samples from disease stricken herds were tested for antibodies against BVD-, Pi₃-, and IBR-virus as well as *Chlamydia*. Low positive titres were observed but for BVDV. The result indicates that a thus far unidentified virus might be the primary cause of this enzootically occurring disease.

¹ National Veterinary Institute, S-750 07 Uppsala, Sweden.

² Department of Virology, Faculty of Veterinary Medicine, Swedish University of Agricultural Sciences, S-750 07 Uppsala, Sweden.

³ Department of Pathology, Faculty of Veterinary Medicine, Swedish University of Agricultural Sciences, S-750 07 Uppsala, Sweden.

Rangifer, Special Issue No. 1, 1986: 369 - 373

Introduction

During the winter 1980 the Tornedalen area along the Swedish/Finnish border was hit by grazing difficulties for the reindeer herds. Thus supplementary feeding was organized at several places from December through April. Mostly this turned out well but at some places animals were taken ill, mostly showing loss of appetite and signs of fever. Sudden deaths also occurred.

This paper deals with the pathological lesions found in animals sent in for necropsy at the National Veterinary Institute, Uppsala, Sweden. In addition blood samples, for serological investigation, were obtained from flocks or reindeer on feeding sites where animals had succumbed (Reh binder *et al.* 1985).

Material and methods

1. Animals

The eight reindeer autopsied in this investigation had all been subjected to artificial feeding in

groups of different sizes and at different places. For most of the reindeer this feeding started up in mid-December. The feed usually consisted of a minor amount of commercial feed-mixture and hay *ad lib*.

For most of the reindeer the feeding period was spent in permanent pens but at some places the pens were regularly shifted to untouched land in order to provide the animals with fresh snow as water supply.

2. Pathological investigations

The eight dead animals which were sent to the National Veterinary Institute, were all in a state of beginning decomposition. Age was estimated on the basis of dental wear.

The preparation of tissue samples for histological as well as ultrastructural studies were performed according to commonly used techniques.

3. Serological investigations

Bloodsamples (2 samples, 6 weeks interval, from each animal) were drawn from the jugular vein of 26 animals at selected feeding sites where sudden deaths had occurred. From three of these herds dead animals were brought in for necropsy, from Hedenäset, Övertorneå I and Männikkö.

Serological tests were carried out against bovine virus diarrhoea (BVD), parainfluenza-3 (Pi3), and infectious bovine rhinotracheitis (IBR) virus as well as against *Chlamydia*.

Results

The results of *post mortem examination* of eight reindeer have been put together in a condensed form in Table 1. From a pathological point of view two reindeer (nos 2 and 5) differed from the rest of the animals autopsied as they had succumbed to differing diseases, a sequestered hoofbone and inanition, respectively. Of the remaining six animals, intracytoplasmic inclusion bodies were seen in the tissue surrounding oral ulcers in four animals.

The ultrastructural examination was affected by the fact that the material obtained showed varying degrees of post mortal changes. The presence of intracytoplasmic inclusion bodies, however, was confirmed. Some cells contained more than one inclusion body. They appeared round or oval with a single membrane and with a granular proteinlike content. Many inclusions, however, were only partly filled or almost empty. Inclusions were regularly located close to and compressing the nuclei into a crescent shape. The compressed nuclei showed a marked condensation of the chromatin but with areas of less electrone density in which varying patterns of granular and fibrillar components were present. In these areas were also regularly observed oval or elongated structures with an average diameter of 40 - 50 nm. Cells either revealed dispersed cytoplasmic organelles or a condensation of the cytoplasm with an increased electron density. A constant feature was clumping of tonofilaments and inter- and intracellular oedema.

A *Fusobacterium necrophorum* infection was histologically and/or bacteriologically establis-

Table 1. Pathological findings and bacterial infections.

No.	Sex	Age	Diagnosis	Bacterial infection
1	♀	8 months	Necrotizing gingivitis Alveolar cell pneumonia Purulent pleuritis	Beta-haemolyzing streptococci (gingiva) Coli (lungs)
2	♂	8 months	Sequestration of hoofbone Sepsis	<i>Corynebacterium pyogenes</i> (hoof) Coli
3	♀	6 years	Inanition. Ulcerative stomatitis. Vesicle formation, intracytoplasmic inclusion bodies.	Coli (whole case)
4	♀	6 years	Ulcerative necrotizing glossitis and gingivitis. Vesicle formation, intracytoplasmic inclusion bodies.	<i>Fusobacterium necrophorum</i> (gingiva, tongue) (by histology) Non-haemolyzing streptococci (lung, spleen)
5	♂	8 months	Inanition	— — —
6	♀	5 - 6 years	Purulent necrotizing glossitis. Vesicle formation, intracytoplasmic inclusion bodies. Purulent necrotizing pleuropneumonia	<i>Corynebacterium pyogenes</i> (tongue) Coli (lung, liver, spleen)
7	♀	10 months	Necrotizing pleuropneumonia and pericarditis	<i>Fusobacterium necrophorum</i> (lung) (by histology and bacteriology)
8	o	2 years	Necrotizing stomatitis and glossitis Vesicle formation, intracytoplasmic including bodies. Necrotizing ruminitis.	<i>Fusobacterium necrophorum</i> (mouth and rumen) (by histology and bacteriology)

hed in three of the four reindeer with inclusion bodies.

The result of the serosurvey is shown in Table 2. Only a few mild reactions against the IBR, Pi3 and *Chlamydia* antigens were recognized.

Discussion

In reindeer mouth lesions, not seldom infected with *Fusobacterium necrophorum*, has been observed several times in connection with supplementary feeding (Rehbinder and Nordkvist, 1983), while outbreaks of foot rot, which earlier were rather common (Horne, 1897;

Nordkvist, 1966; Skjenneberg and Slagsvold, 1968), today are rare (Rehbinder and Nordkvist, 1983).

In the majority of the cases autopsied (five out of eight) mouth lesions (glossitis, gingivitis and stomatitis) were found and of these two were infected with *F. necrophorum* (Table 1). One of the remaining animals had died from a necrotizing pleuropneumonia and a pericarditis caused by *F. necrophorum*. The entrance port of the infection could not be determined. Of the additional two animals one died from sepsis emanating from a hoof lesion infected by *C.*

Table 2. Results of serological investigation

Herd	Animal no.	Sex	Age	BVD		Pi 3		IBR		<i>Chlamydia</i>	
				3/3	17/4	3/3	17/4	3/3	17/4	3/3	17/4
Hedenäset	1	♀	ad	<5	<5	<8	<8	0	0	0	0
	2	♀	ad	<5	<5	<8	16	0	0	4	0
	3	♂	ad	<5	<5	8	<8	0	0	8	0
	4	♀	ad	<5	<5	<8	<8	0	0	0	2
	5	♂	ad	<5	<5	<8	<8	0	0	0	2
	6	♂	ad	<5	<5	8	16	8	16	0	0
	7	♀	22 m	<5	<5	8	16	0	0	16	2
	8	♀	10 m	<5	<5	<8	<8	0	0	4	0
	9	♀	10 m	<5	<5	16	16	0	0	4	0
Övertorneå I	10*	♀	ad	<5	<5	<8	<8	0	0	0	2
	11*	♀	22 m	<5	<5	16	16	0	0	0	0
	12*	♀	ad	<5	<5	8	8	0	0	0	0
Männikkö	13	♀	ad	<5	<5	16	16	0	0	2	0
	14	♀	10 m	<5	<5	8	8	0	0	0	0
	15	♂	10 m	<5	—	<8	—	0	—	0	—
	16	♀	ad	<5	<5	8	8	0	0	2	2
	17	♀	ad	<5	<5	<8	<8	0	0	0	8
	18	♀	ad	<5	<5	16	16	0	0	0	0
	19	♀	10 m	<5	<5	<8	<8	0	0	0	0
	20	♀	ad	<5	<5	<8	<8	4	4	8	0
	21	♀	ad	<5	<5	8	16	0	0	0	0
	22	♀	ad	<5	<5	<8	<8	0	0	0	4
Övertorneå II	23*	♀	ad	<5	<5	0	<8	0	0	0	0
	24	♀	ad	<5	<5	8	8	0	0	0	0
	25	♀	ad	<5	<5	8	8	4	8	2	0
	26*	♀	ad	<5	<5	16	16	0	0	0	0

ad = adult.

m = months.

* = has shown clinical signs of disease.

pyogenes while the other died from inanition most probably due to indigestion. Thus the main findings in the autopsied animals are the epithelial lesions of the oral cavity. The histological and electron microscopical investigations may be indicative of a virus infection but the micrographs, however, did not reveal any virus particles.

As the material, concerning all cases, was obtained a considerable time after the death of the animal no conclusive alterations but for intracytoplasmic inclusions, vesicle formations and epithelial ulcers could be established.

The prevalence of antibodies against BVD-virus in reindeer has earlier been demonstrated (Elazhary *et al.*, 1981; Dietrich, 1981). None of the animals tested in this investigation had antibodies against BVD. Neither did the histological picture of the lesions found in the necropsied animals indicate infection with BVD-virus.

Some animals had a low antibody titre against Pi₃-virus (Table 2) but the oral lesions found in the necropsied animals cannot be connected with this disease.

In Finnish reindeer Ek-Kommonen *et al.* (1982) found a high frequency of antibodies against IBR and Dietrich (1981) reports on similar results from Alaska. According to Ek-Kommonen *et al.* (1982) the presence of a closely related cross-reacting herpes-virus cannot be excluded.

Antibodies against *Chlamydia* has been reported in Finnish reindeer (Neuvonen, 1976). Its significance for the health of reindeer has not been established. Of the animals tested eight were considered mildly positive. The morphology of the oral lesions did not, however, indicate any *Chlamydia* infection.

It seems apparent that none of the serologically investigated agents are responsible for the epithelial lesions found in the oral cavity of five out of eight animals necropsied. The histopathological and electron microscopical investigations rather indicate some similarities with pox-virus infections (Crandell and Grosser, 1974; Fenner, 1979; Pospischil and Bachman, 1979).

Already in 1897 Horne described the entity of «foot rot» in reindeer as often producing two different diseases at the same time, one affecting the hoof and the other affecting the oral cavity. Also Skjenneberg and Slagsvold (1968) reports

on a mouth disease which can be quite reminiscent of calf diphtheria.

Principally, any lesion of the oral mucosa whether caused by traumata, foreign bodies, parasites or a primary infection may give different wound bacteria the opportunity of penetrating into the submucosa and underlying tissues. Thus the varying pattern of the mouth lesions may depend on the type of the secondarily invading bacteria.

The possibility of a primary virus infection, as indicated in this paper, may explain the rapid spread of mouth lesions in herds of reindeer as reported by Horne (1897), Nordkvist (1966) and Skjenneberg and Slagsvold (1968) and observed in this investigation. Attempts to isolate a virus have, however, not yet been performed.

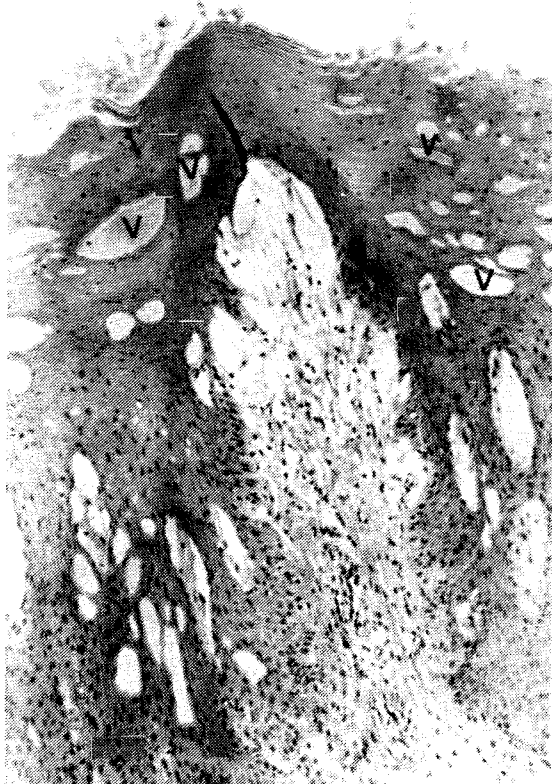

Fig. 1. Tongue of reindeer. Note numerous vesicles (V) and oedema HEx70

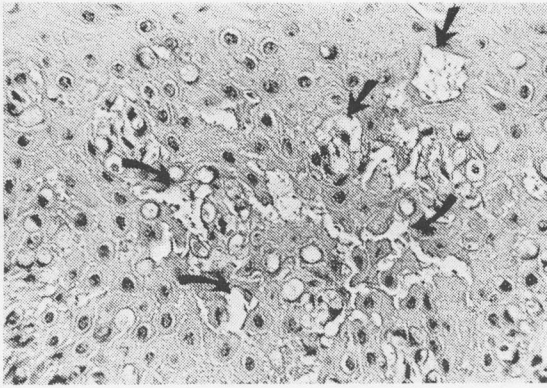


Fig. 2. Tongue of reindeer. Note vesicle formation (arrows) HEx280

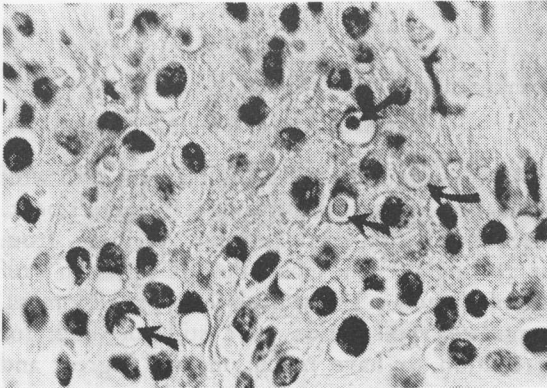


Fig. 3. Lip of reindeer. Note numerous intracytoplasmic inclusion bodies (arrows) HEx1000

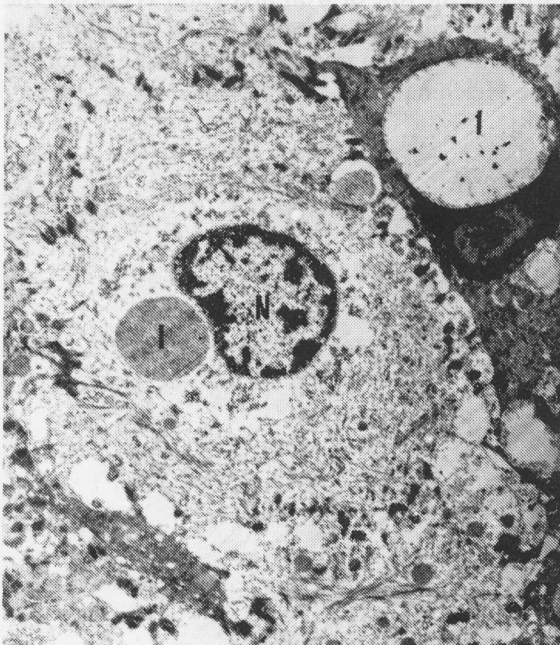

Fig. 4. Electron micrograph of epithelial cells from tongue of reindeer. Note inclusion bodies (I) and compressed nuclei (N) x6000

References

- Crandell, R. A. and Gosser, H. S. 1974. Ulcerative esophagitis associated with poxvirus infection in a calf. — *Journal of the American Veterinary Medical Association*. 165: 282 - 283.
- Dietrich, R. A. 1981. Respiratory viruses. — In: Dietrich, R. A. (ed.). *Alaskan Wildlife Diseases*. University of Alaska, Fairbanks, Alaska.
- Ek-Kommonen, C., Veijalainen, P., Rantala, M. and Neuvonen, E. 1982. Neutralizing antibodies to bovine herpesvirus 1 in reindeer. — *Acta Veterinaria Scandinavica*. 23: 565 - 569.
- Elazhary, M.A.S.Y., Frechette, J.L., Silim, A. and Roy, R.S. 1981. Serological evidence of some bovine viruses in the caribou (*Rangifer tarandus caribou*) in Quebec. — *Journal of Wildlife Diseases*. 17: 609 - 612.
- Horne, H. 1897. Renens klovsyge. (The reindeer hoofdisease). — *Den Norske Veterinærtidsskrift*.
- Fenner, F. 1979. Portraits of viruses: The poxviruses. — *Intervirology*. 11: 137 - 157.
- Neuvonen, E. 1976. Occurrence of antibodies to group specific chlamydia antigen in cattle and reindeer sera in Finnish Lapland. — *Acta Veterinaria Scandinavica*. 1976: 363 - 369.
- Nordkvist, M. 1966. Ekonomisk renskötsel (Economic reindeer husbandry). — *LT's Förlag, Stockholm*.
- Pospischil, A. and Bachmann, D. 1980. Nuclear changes in cells infected with parapoxviruses stomatitis papulosa and orf: An in vivo and in vitro ultrastructural study. — *Journal of General Virology*. 47: 113 - 121.
- Rehbinder, C. and Nordkvist, M. 1983. Granulom i tungan på ren (*Rangifer tarandus* L) (Granulomas in the tongue of reindeer (*Rangifer tarandus* L)). — *Rangifer* 3: 47 - 50.
- Rehbinder, C., Nordkvist, M., Moreno, J. W. & Siddiqui, I-U-D. 1985. A suspected virus infection of the oral mucosa in Swedish reindeer (*Rangifer tarandus* L). *Rangifer* 5: 22 - 31.)
- Skjenneberg, S. and Slagsvold, L. 1968. Reindriften og dens naturgrunnlag (Reindeer husbandry and its ecological principles). — *Scandinavian University Books. Universitetsforlaget, Oslo*. 332 p.